

Case report:

Preserving Hemithyroid During Total Laryngectomy: Report of a Disease-Free & Complication-Free Case

Kumareysh Vijay V¹, Mohd Azizul Fitri Khalid¹, Irfan Mohamad²

Abstract

Preserving hemithyroid intraoperatively in a total laryngectomy operation is uncommon, as this procedure normally leads to high rate of hypothyroidism similar to total thyroidectomy. This has caused most of the surgeons to prefer total thyroidectomy when involvement of the thyroid gland is suspected. We report a rare case of total laryngectomy with preservation of one lobe of thyroid gland in a 57-year-old man with left unilateral transglottic laryngeal carcinoma. Post operatively the patient was well without signs and symptoms of hypothyroidism or hypocalcemia. The patient was not started on any hormone or calcium supplements after the surgery.

Keywords: Laryngeal Cancer; Laryngectomy; Thyroidectomy

*International Journal of Human and Health Sciences Vol. 02 No. 03 July'18 Page : 170-173
DOI: <http://dx.doi.org/10.31344/ijhhs.v2i3.50>*

Introduction

Thyroid hormone level post total laryngectomy remains a concern for most of the surgeons. Removing thyroid totally during laryngectomy can often results in severe complications like hypothyroidism and hypocalcemia requiring life-long thyroid hormone and calcium replacement.¹ Although, total thyroidectomy possess a significant risk of hypothyroidism and hypocalcemia, this procedure still being carried out to avoid leaving residual disease which may cause recurrence later on. This is due to the close anatomical relationship of thyroid gland and larynx which can cause direct extension or microinvasion of tumor.²

Case Summary

A 57-year-old Indian man with underlying diabetes mellitus, dyslipidemia and chronic smoker presented with hoarseness for 2-month duration. There was no history of dysphagia, odynophagia or shortness of breath. On examination, there was no audible stridor, voice appeared hoarse, with good cough. There was no palpable lymph nodes, laryngeal crepitus present, and the thyroid gland was normal in size and non-tender. Flexible nasopharyngolaryngoscopy showed a mass at anterior two-thirds of the left vocal cord extending

down to left subglottic region. The anterior commissure and right vocal cord were free of mass. Biopsies were taken from both sites, the left vocal cord and left subglottis. Both biopsies came back as moderately differentiated squamous carcinoma. Computed tomography (CT) scan confirmed the left vocal cord lesion extending to subglottic region with no erosive changes of thyroid and cricoid cartilage. There was no distant metastasis.

The patient underwent total laryngectomy with left hemithyroidectomy as clinically the lesion was only extending subglottically to left side and no erosive changes seen over the thyroid or cricoid cartilage from the CT scan. The right lobe of thyroid gland was preserved. This was done by exposing the right thyroid lobe before dividing it from the isthmus medially about 1 cm from the midline. Superiorly, right thyroid lobe was released from the larynx and trachea cartilage inferiorly through the median. Berry's ligament on the right lobe was released and the rest of laryngotracheal framework was dissected away from the right thyroid lobe. All right thyroid vessels were preserved including superior thyroid artery and inferior thyroid artery vascular pedicles. Dissection continued until

1. Department of Otorhinolaryngology, Hospital Raja Permaisuri Bainun, Ipoh, Perak, Malaysia
2. Department of Otorhinolaryngology Head & Neck Surgery, School of Medical Sciences, niversiti Sains Malaysia, Kota Bharu, Kelantan, Malaysia

Correspondence to: Irfan Mohamad, Department of Otorhinolaryngology-Head & Neck Surgery, School of Medical Sciences, Universiti Sains Malaysia Health Campus, 16150 Kota Bharu Malaysia. Email: irfankb@usm.my

the right posterior border of larynx and right tracheoesophageal groove seen. The right recurrent laryngeal nerve was identified and divided. The preserved thyroid lobe was positioned medial to right sternocleidomastoid muscle (Figure 1). Histopathology report of the laryngectomy specimen (Figure 2) was reported as moderately

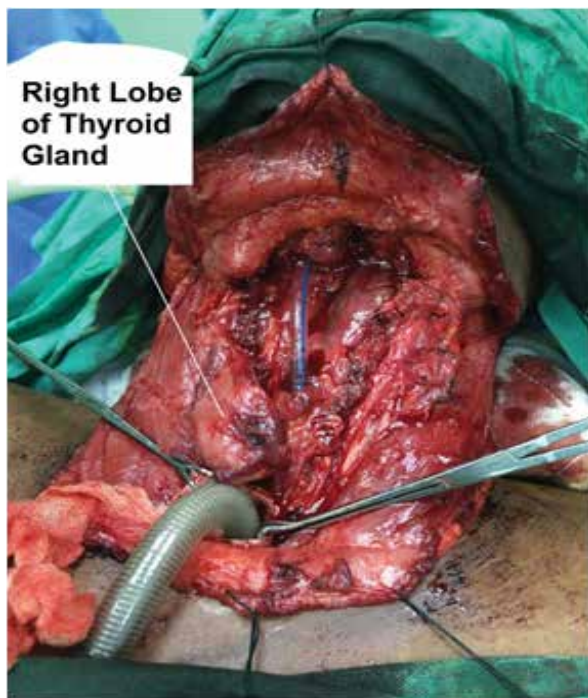

Figure 1: Post total laryngectomy and left hemithyroidectomy

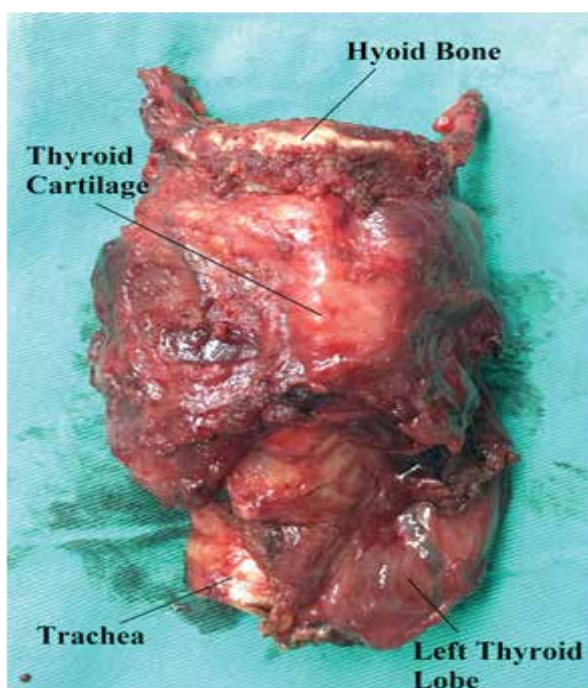


Figure 2: Specimen sent for histopathological examination

differentiated squamous cell carcinoma with all margins clear. Whereas the histopathological report of left thyroid lobe showed variable sizes of thyroid follicles lined by a layer of cuboidal epithelial cells containing homogenous colloid material. No tumor deposit seen in thyroid tissue. Post operatively thyroid function test and calcium level was monitored. Corrected calcium level on day 1 post operation was 2.20 mmol/L, on day 7 post operation was 2.38 mmol/L, and on day 14 post operation was 2.26 mmol/L. Free thyroxine (Free T4) level one week post operation was 14.5 pmol/L and two weeks post operation was 14.1pmol/L whereas thyroid stimulating hormone (TSH) one week post operation was 6.59mIU/L and two weeks post operation was 3.69mIU/L. Clinically patient did not have any symptom and sign of hypothyroidism or hypocalcemia. Thyroid function test and calcium level was repeated 2 months post operation. Free T4 level was 10.7 pmol/L, TSH was 4.62 mIU/L and corrected calcium level was 2.27 mmol/L. Patient remain euthyroid despite slight decrease in T4 level.

Discussion

Total laryngectomy has always been accompanied by total thyroidectomy, which has led to many post-operative complications such as hypocalcaemia and hypothyroidism which has caused increase hospital stay and cost of treatment.¹ There have been reported cases of thyroid gland invasion in laryngeal carcinoma patients, although it is rare. Tumors with subglottic involvement or very advanced tumors have a higher chances and prevalence of causing thyroid gland invasion.³ Common complications of total laryngectomy are thyroid and parathyroid dysfunctions.⁴ However, we have performed total laryngectomy with preservation of hemithyroid with the aim to reduce the morbidity of hypothyroidism and hypocalcaemia. Post operatively his thyroid function test hormones and calcium level was normal and patient does not develop hypothyroidism or hypocalcemia. Patient was not started on any thyroid or calcium supplements post operatively. Not all total laryngectomy must be accompanied by total thyroidectomy.^{5,6} There is still a lot of contradicting issues and opinions on hemithyroidectomy during total laryngectomy especially in cases where there is no obvious demarcation of thyroid gland involvement. There was no evidence of thyroid cartilage invasion on imaging in our case. It is known that thyroidectomy is not compulsory in all

patients going for total laryngectomy.^{5,7,8} Extension of tumor subglottically, thyroid cartilage invasion, and pyriform sinus involvement are the indications for hemithyroidectomy and isthmectomy, rather than total thyroidectomy.⁸

Thyroid gland involvement in laryngeal carcinoma patients is rare and only account for 7.7%.⁶ It happens most probably due to either metastasis via local regional lymphatics or direct invasion.⁴ Anatomically subglottis, paraglottic space, cricothyroid space, thyroid cartilage, and cricothyroid membrane lie very close to each other which helps to explain further regarding the thyroid gland involvement and extension in advanced stage laryngeal tumors.⁷

Hemithyroidectomy still poses a risk of hypothyroidism with an incidence of 5.0% to 41.9% in all patients underwent hemithyroidectomy. The etiology causing hypothyroidism in hemithyroidectomy patients still remain uncertain.⁹ In our daily life, in order for us to remain euthyroid, thyrocytes produced by one thyroid lobe is enough and with that believe many doctors choose to do hemithyroidectomy as to reduce the usage of postoperative thyroid hormone therapy. However, other problems

such as high preoperative TSH levels, elevated concentrations of thyroid autoimmune antibodies, degree of thyroiditis, age, and residual thyroid volume may reduce thyroid hormone production postoperatively. New studies and research have suggested that TSH be measured at 6 and 12 months post operation. Repeating thyroid hormone level earlier at 3 months may show high values which may normalize over time. This followup timeline allows for a better surveillance, especially in patients managed conservatively.¹⁰

Conclusion

Preserving hemithyroid during total laryngectomy in laryngeal carcinoma patients will reduce the complications of hypocalcemia and hypothyroidism. In long run, this can reduce hospital stay and treatment expenses. Not all total laryngectomy has to be accompanied by total thyroidectomy, hemithyroidectomy is proven to be an alternative depending on the stage and extension of the disease, especially in cases with unilateral subglottic extension of tumor with no erosive changes or lesion over the thyroid and cricoid cartilage. Long term followup schedule is needed to monitor thyroid function test, calcium level and also to monitor tumour recurrence.

References

1. Tredici P, Grosso E, Gibelli B, Massaro MA, Arrigoni C, Tradati N. Identification of patients at high risk for hypocalcemia after total thyroidectomy. *ACTA Otorhinolaryngologica Italica* 2010;30:144-148.
 2. Harrison DF. Thyroid gland in the management of laryngopharyngeal cancer. *Arch Otolaryngology* 1973;97:301-302.
 3. AlKhatib T, Mendelson AA, Kost K, Zeitouni A, Black M, Payne R, et al. Routine thyroidectomy in total laryngectomy: is it really indicated?. *J Otolaryngol Head Neck Surg.* 2009 Oct;38(5):564-567
 4. Hegazy MA, Hassouna MS, El-Fattah AF, Hassan OM. Thyroid and parathyroid dysfunction after total laryngectomy. *Med. J. Cairo Univ.* 2015 Sept;83(1):609-614.
 5. Ceylan A, Koybaşıoğlu A, Yılmaz M, Uslu S, Asal K, Inal E. Thyroid gland invasion in advanced laryngeal and hypopharyngeal carcinoma. *Kulak Burun Bogaz Ihtis Derg.* 2004;13(1-2):9-14.
 6. Rakesh B, Bharathi M, Babu A. Thyroid gland involvement in laryngeal and hypopharyngeal carcinoma. *J. Evid. Based Med. Healthc.* 2016 Feb;3(17):693-695.
 7. Mourad M, Saman M, Sawhney R, Ducic Y. Management of the thyroid gland during total laryngectomy in patients with laryngeal squamous cell carcinoma. *The Laryngoscope.* 2015;1(1):1-4.
 8. Nikakhlagh S, Saki N, Ranjbari N, Fasihy A, Nezami P. Elective hemithyroidectomy during total laryngectomy. *The Iranian J Otorhinolaryngology* 2009;20(54):197-200.
 9. Miller FR, Paulson D, Prihoda TJ, Otto RA. Risk factors for the development of hypothyroidism after hemithyroidectomy. *Arch Otolaryngol Head Neck Surg.* 2006 Jan;132:36-38.
 10. Lee J, Chung WY. Hypothyroidism after hemithyroidectomy: incidence, risk factors, natural history and management, hypothyroidism influences and treatments [Internet]. Shanghai: InTech; 2012 Feb 08 [cited 2017 Dec 15]. 35-50. Available from: <https://www.intechopen.com/books/hypothyroidism-influences-and-treatments/hypothyroidism-after-thyroid-lobectomy-incidence-risk-factors-natural-history-and-management>
-