

**Case report:**

**Atrial Myxoma? But it's not.**

*Nik Ramziah A.S<sup>1</sup>, Nor Hidayah Z.A<sup>2</sup>, Anas S.R<sup>3</sup>, Nazri M<sup>4</sup>, Nazri A<sup>5</sup>, Azerin O<sup>6</sup>.*

**Abstract**

Postpartum period carries high risk of pulmonary embolism due to hypercoagulability state. Pulmonary embolism (PE) should be suspected in postpartum patient who has short history of progressing right heart failure without underlying heart disease. We report a case of pulmonary embolism with large right atrial thrombus without deep vein thrombosis in a 27 years old lady, para 1+2, post-delivery day 30 who presented with sudden onset of dyspnea and giddiness. She was diagnosed with right atrial thrombus complicated by acute pulmonary embolism. An emergency operation was performed and intraoperatively a pedunculated mobile mass is attached to the right atrial wall mimicking atrial myxoma, with incidental finding of patent foramen ovale. The mass was removed and concomitant pulmonary embolectomy was performed. The postoperative course was uneventful with the patient subsequently discharged.

**Keyword:** Atrial myxoma, post-partum, pulmonary embolism.

*International Journal of Human and Health Sciences Vol. 02 No. 03 July'18 Page : 155-157  
DOI: <http://dx.doi.org/10.31344/ijhhs.v2i3.45>*

**Case Presentation**

A 27 year-old lady, para 1+2, day 30 post vaginal delivery with no medical illness presented with dyspnea and giddiness for two days. Upon examination, the patient was tachypneic, hypotensive and the patient was hypoxic with reduced air entry on both lungs. Other clinical examinations were unremarkable including deep vein thrombosis examination. All the blood results were normal except the arterial blood gas showed type II respiratory failure. The ECG showed sinus tachycardia with evidence of right heart strain and S1QIIIITIII pattern. The patient was intubated in view of impending cardiorespiratory collapse, required inotropic support and was stabilized in ICU. The echocardiogram (ECHO) showed

pedunculated mobile mass measuring 1.2 cm × 1.9 cm arise near the opening of inferior vena cava (IVC) with dilated right atrium and right ventricle, and hyper contractility of right ventricular apex (McConnell's sign). Mild tricuspid regurgitation was present with pulmonary artery systolic pressure (PASP) of 54 mmHg. The differential diagnosis included thrombus or myxoma, but due to morphology and mobility of the intra-atrial mass, it was difficult to differentiate one from the other.

Color Doppler and duplex-scan ultrasonography of the lower limbs were not suggestive for deep venous thrombosis (DVT). Computed tomography pulmonary angiogram (CTPA) was carried out and suggestive of PE with the presence of filling defect

1. AS Nik Ramziah, Cardiothoracic Surgery Unit Hospital Raja Perempuan Zainab II, Kota Bharu Kelantan, Malaysia
2. ZA Nor Hidayah, Anaesthesiology Department Hospital Raja Perempuan Zainab II, Kota Bharu, Kelantan, Malaysia.
3. SR Anas, Cardiothoracic Surgery Unit Hospital Raja Perempuan Zainab II, Kota Bharu Kelantan, Malaysia.
4. M Nazri, Anaesthesiology Department Hospital Raja Perempuan Zainab II, Kota Bharu, Kelantan, Malaysia.
5. A Nazri, Anaesthesiology Department Hospital Raja Perempuan Zainab II, Kota Bharu, Kelantan, Malaysia.
6. O Azerin, Cardiology Unit, Internal Medicine Department, Hospital Raja Perempuan Zainab II, Kota Bharu, Kelantan, Malaysia.

**Correspondence to:** Nor Hidayah Zainool Abidin, Anaesthesiology Department Hospital Raja Perempuan Zainab II, Kota Bharu, Kelantan, Malaysia. Email: nhza85@yahoo.com

in the bifurcation of pulmonary trunks into right and left pulmonary arteries. The pedunculated mass in the right atrium was suggested to be a blood clot.

An emergency operation was performed and intraoperatively, the right ventricle, right atrium and main pulmonary artery appeared to be distended and struggling. Fortunately, there was incidental finding of small patent foramen ovalet that allow right to left blood shunt during obstructive shock. The right atrial appendage was full with blood clots and the pedunculated blood

clot attached to the coronary sinus was identified and was removed completely. It was able to be closed directly. The pulmonary embolectomy was carried out and several fragments of clots were removed from the distal parts of both pulmonary arteries.

Postoperatively, the patient condition improved markedly. She was able to be extubated on day two post-operative and was able to be discharged on day 10. She received anticoagulation therapy for treatment and prevention of recurrent pulmonary embolism.

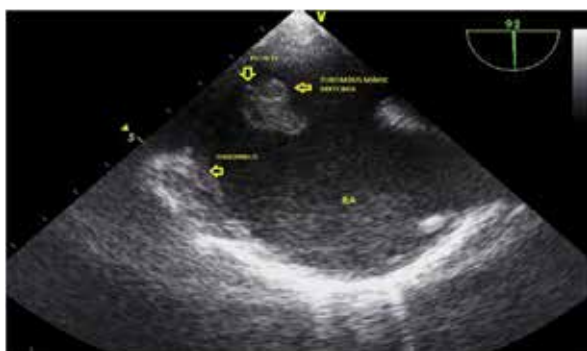

Fig 1: Transesophageal echocardiography (TOE) showed a pedunculated freely mobile mass.

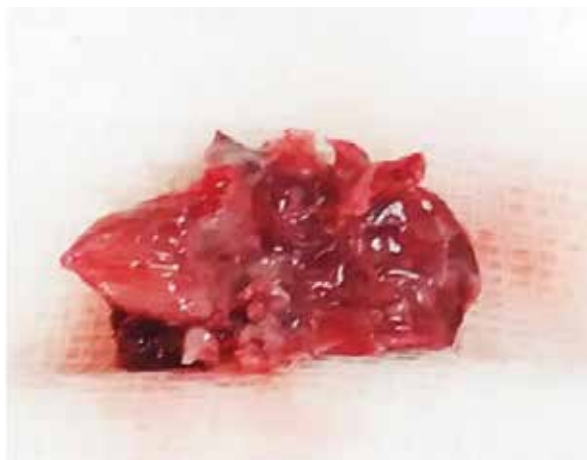


Fig 2: The operative specimen showed pedunculated mass with irregular surfaces.

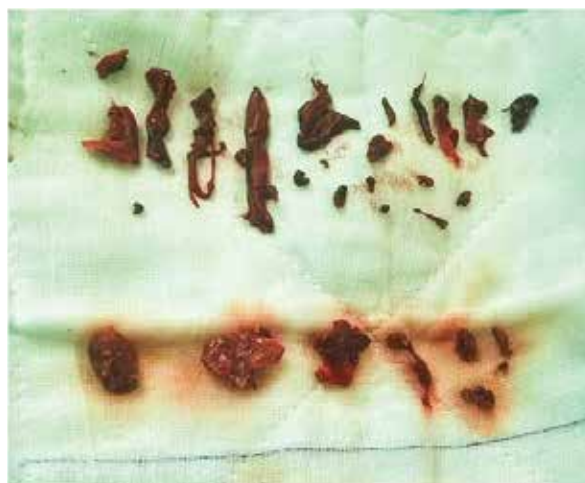

Fig 3: Blood clots removed from patient's pulmonary trunk and right atrium.

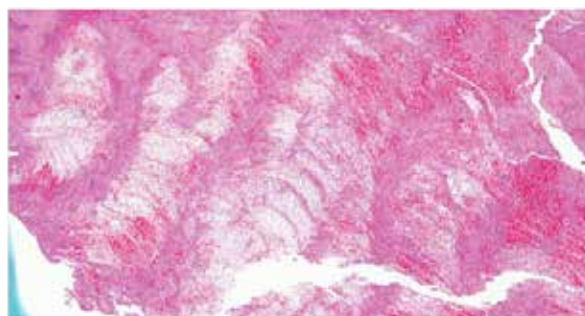


Fig4: Histologic examination shows an organized thrombus with presence of lines of Zahn.

### Discussion

Postpartum period associated with increased risk of PE. Studies showed that the risk period extended for four weeks following delivery. Event rates for PE approached those of the general population of reproductive-age women by the end of four weeks postpartum<sup>1</sup>. This patient did not have other risk factors which can be associated with PE such as trauma, obese, prolong immobilization and surgery. She also does not know to have underlying inflammatory disease. Usually PE is known as a consequence of DVT<sup>2</sup>. However in this case, there was no identifiable source on lower extremity on venous duplex imaging. Meanwhile,

the presence of right atrial thrombus can develop in several situations where it might arise from venous emboli that have become entrapped in the right heart. This usually appear as mobile, irregular masses that float freely in the right atrium<sup>3</sup>. Our patient had a highly mobile and friable mass, but it was not floating freely in the right atrium. The large thrombus was attached to the free wall of the right atrium, highly suggested a myxoma. In this case, the morphological characteristics of atrial mass which described using echocardiography also suggestive of myxoma. The imaging appearance of thrombi sometimes can mimic the appearance of myxoma. Eventhough ECHO

is the most commonly used diagnostic modality for such cases, the distinction between myxomas and thrombi may pose considerable diagnostic challenges, and thus difficult cases have been reported<sup>4,5</sup>. Cardiac myxoma on the other hand is the most common primary cardiac tumour. About 15% of atrial myxomas arise in the right atrium, and they are usually attached to the inter-atrial septum<sup>3</sup>. Although the mechanism of right atrial thrombus formation in our case most probably due to hypercoagulability state in postpartum period, it is important to continue anticoagulation therapy after surgery to avoid recurrence and further

investigation need to be carried out in order to identify other risk factors.

### **Conclusion**

PE with right atrial mass is usually associated with either thrombus or cardiac myxoma. However, in postpartum patient, there is still high risk formation of intracardiac clots without having DVT due to hypercoagulability state. The finding of an intracardiac echogenicity in patient may pose diagnostic challenge. However, early diagnosis and surgical intervention is crucial since it is associated with short term significant morbidity and long term survival.

---

### **References**

1. Morris, J. M., Algert, C. S., & Roberts, C. L. (2010). Incidence and risk factors for pulmonary embolism in the postpartum period. *Journal of Thrombosis and Haemostasis*, 8(5), 998–1003. doi:10.1111/j.1538-7836.2010.03794.x
2. Schwartz, T., & Hingorani, A. (2011). PS154. Pulmonary embolism without deep venous thrombosis. *Journal of Vascular Surgery*, 53(6), 70S.
3. Cianciulli, T. F., Saccheri, M. C., Redruello, H. J., Cosarinsky, L. A., Celano, L., Trila, C. S., Parisi, C.E., & Prezioso, H. A. (2008). Right atrial thrombus mimicking myxoma with pulmonary embolism in a patient with systemic lupus erythematosus and secondary antiphospholipid syndrome. *Texas Heart Institute Journal*, 35(4), 454–457.
4. Feinglass, N. G., Reeder, G. S., Finck, S. J., Shine, T. J., & Maniu, C. V. (1998). Myxoma of the left atrial appendage mimicking thrombus during aortic valve replacement. *Journal of the American Society of Echocardiography*, 11(6), 677–679.
5. Hesse, B., Murphy, R. T., Myles, J., Huang, J., & Sabik, E. M. (2006). A left atrial appendage thrombus mimicking atrial myxoma. *Circulation*, 113(11), e456–e457.