

Case report:

A Caecal Lipoma with Pseudomalignant Features and Colo-colonic Intussusception.

Fatimah Mastura Ishak¹ and Juhara Haron²

Abstract

Gastrointestinal lipomas are rare benign non-epithelial tumours, usually single and slow growing. Most of colonic lipomas were detected incidentally during surgery, endoscopy or autopsy with incidence ranges from 0.2% to 4.4%. While lesion measures smaller than 2cm in diameter are usually asymptomatic, a larger lesion more than 2cm, can cause symptoms such as intestinal obstruction, rectal bleeding, intussusception, constipation, diarrhea or prolapse. Pre-operative diagnosis is challenging as symptoms and imaging mimic malignancy. Direct visualization of the submucosal lipoma can be done by endoscopy. It is seen as smooth, rounded yellowish polyps with a thick stalk or broad-based attachment. Its typical features are the “tent sign” (elevation of the mucosa over lipoma with biopsy forceps), “cushion sign” or “pillow sign” (pressing forceps against the lesion results in depression or pillowing of the mass) and the “naked fat sign” (extrusion of yellowish fat at the biopsy site). In some cases, with large sized flat shaped lesion and ulceration may lead to an impression of malignant lesion. If the endoscopic biopsy is not taken at accurate site, for example at inflamed mucosal of adjacent tissue, it can give false impression of “nonspecific colitis”. We describe a patient with persistent diarrhea and hematochezia who underwent open right hemicolectomy for the presumptive endoscopic and imaging diagnosis of caecal adenocarcinoma. However, histological examination confirmed benign caecal lipoma.

Keywords: Colonic lipoma, caecal lipoma, benign intestinal tumour.

International Journal of Human and Health Sciences Vol. 05 No. 01 January'21 Page : 122-126

DOI: <http://dx.doi.org/10.31344/ijhhs.v5i1.247>

Introduction

Gastrointestinal lipomas are rare benign non-epithelial tumours, usually single and slow growing. Most of colonic lipoma usually detected incidentally during surgery, endoscopy or autopsy¹. Most literatures reported its incidence ranges from 0.2 percent to 4.4 percent². In patient with lesion measures smaller than 2cm in diameter, they are usually asymptomatic. If the intestinal lipoma is larger than 2cm, it can cause symptoms such as intestinal obstruction, rectal

bleeding, intussusception, constipation, diarrhea or prolapse. Pre-operative diagnosis is challenging as symptoms and imaging mimic malignancy³. Direct visualization of the submucosal lipoma can be done by performing endoscopy. It is seen as smooth, rounded yellowish polyps with a thick stalk or broad-based attachment. Its typical features are a smooth, spherical polyp, usually sessile, slightly yellowish in colour while the overlying mucosa is intact. Other typical features are the “tent sign” (elevation of the mucosa over

1. Dr. Fatimah Mastura Ishak, Postgraduate Radiology candidate, Department of Radiology, School of Medical Sciences, Universiti Sains Malaysia, Health Campus, 16150 Kubang Kerian, Kelantan, Malaysia.
2. Assoc. Prof. Juhara Haron, Senior Lecturer, Department of Radiology, School of Medical Sciences, Universiti Sains Malaysia, Health Campus, 16150 Kubang Kerian, Kelantan, Malaysia.

Correspondence to: Assoc. Prof. Juhara Haron, Senior Lecturer, Department of Radiology, School of Medical Sciences, Universiti Sains Malaysia, Health Campus, 16150 Kubang Kerian, Kelantan, Malaysia. E-mail: drjuhara@usm.my

lipoma with biopsy forceps), “cushion sign” or “pillow sign” (pressing forceps against the lesion results in depression or pillowing of the mass) and the “naked fat sign” (extrusion of yellowish fat at the biopsy site). In some of the cases with large sized flat shaped lesion and ulceration may lead to an impression of malignant lesion. On top of that, if the endoscopic biopsy is not taken at its accurate site, for example at inflamed mucosal of adjacent true lesion, it can give false impression of “nonspecific colitis”⁴. Imaging techniques such as CT and fluoroscopy are widely used to help in narrowing the diagnosis. However, definite diagnosis is made based on histopathological findings. Lesion which is 2cm and less in diameter is subjected for endoscopic removal. Larger lesion must be removed surgically either by open or laparoscopic methods. Although extensive operative technique including colostomy and excision, hemicolectomy or subtotal colectomy are employed, segmental resection remains the technique of choice to most of the surgeons.

Case report

A 60-year-old Malay lady with no known comorbid presented as outpatient with 3 months history of altered bowel habit. She had diarrhea and passed out per rectal blood about 4 times per day, half a cup in amount for each episode. She denied history of constipation or mucus in stool. The patient reported weight loss of 6kg in 3 months. She has no allergy to any medication. No history of cancer in the family.

On physical examination, her vital signs were stable. Abdominal examination revealed normoactive bowel sounds, non-distended abdomen, and diffuse mild tenderness to palpation. Per rectum findings showed brownish stool but no mass. Proctoscope showed no hemorrhoid or mass. Initial laboratory tests including complete blood count showed low Hemoglobin (Hb) count but was normalized after several blood transfusions. The metabolic investigations were normal. CEA value was 0.7(ng/mL). Colonoscopy revealed huge fungating mass at the caecum (Figure 1). However, the endoscopic biopsy result revealed mild edema with granulation tissue. Even though HPE showed benign features, surgeon decided to take out the lesion since symptoms persisted and there was a possibility that biopsy taken was not at accurate site.

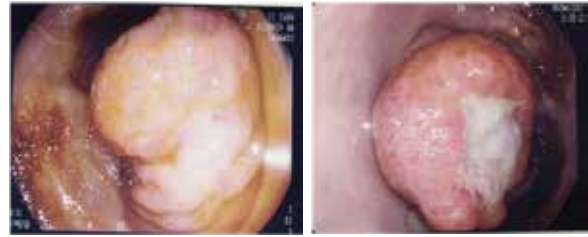

Figure 1: Endoscopic image of huge fungating mass arising from the caecal wall.

CT scan of abdomen and pelvis with PO and IV contrast was performed, which revealed well defined endoluminal mass with multiple septation arising from lateral wall of caecum and HU of -129 measuring 2.0 x 2.7 x 3.1cm (Figure 2a-b). It was associated with luminal narrowing and surrounding heterogenous circumferential caecal wall thickening as well as terminal ileum.

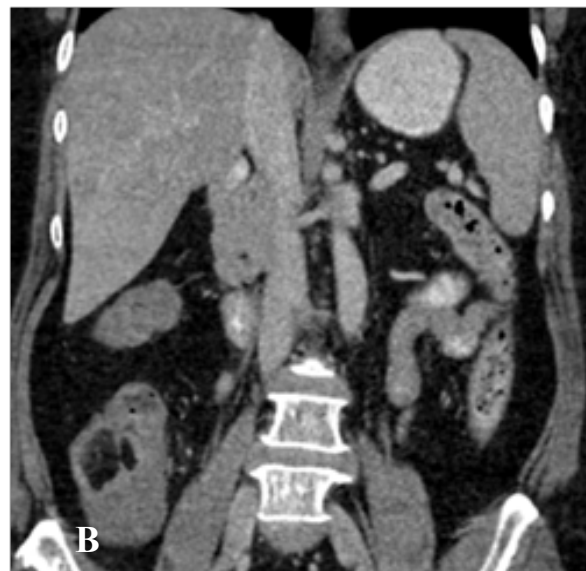
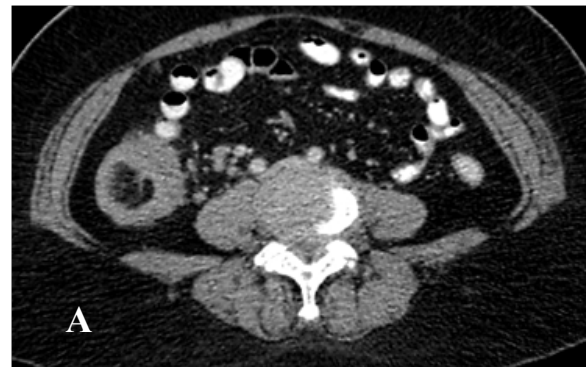
Figure 2a-b: CT Scan showed endoluminal mass with multiple septation arising from lateral wall of caecum.

There was also short segment of intussusception seen proximal to the lesion with evidence of telescoping and claw sign/bowel within bowel sign (Figure 2c). There was no dilated bowel proximally. The appendix was normal. Minimal

streakiness surrounding the ceecal pole with multiple subcentimeter mesenteric nodes seen at that region.

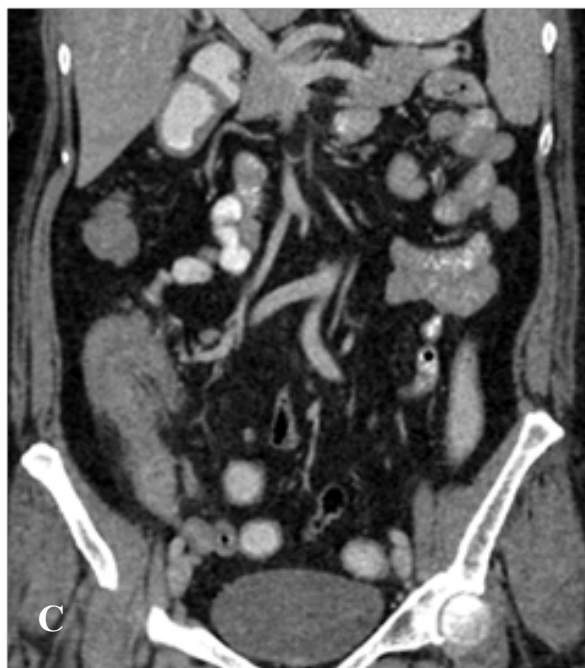

Figure 2c : Claw sign (arrow) suggestive of intussusception.

The patient was subjected for elective surgery with presumption diagnosis of adenocarcinoma of caecum. Right hemicolectomy with end to end anastomoses performed. Intra-operatively, a palpable intraluminal ceecal mass was found, which was concordant with the location found on colonoscopy. No peritoneal nodules noted. The other solid organs are normal. No ascites.

Pathologic evaluation of the right hemicolectomy specimen revealed polypoidal mass, 15mm from ileocecal junction measuring 3.0 x 2.8 x 2.3cm. The mass located submucosally, has solid, soft homogenous yellowish surface and protruding up to the ulcerated mucosa. The polypoidal mass was completely surrounded by mucosa. No gross invasion. Microscopically, it showed circumscribed submucosal lesion consists of uniform mature adipocytes separated by thin intervening fibrous septae. (Figure 3 and 4). The patient was well post operatively, and she was discharged home on regular diet on post-operative day 4. CT imaging 6 months post surgery showed normal abdominal findings.

Discussion

Colonic lipoma is composed of well differentiated adipose tissue supported by fibrous tissue in which are relatively uncommon tumors of mesenchymal origin. It arises from submucosal layer, may

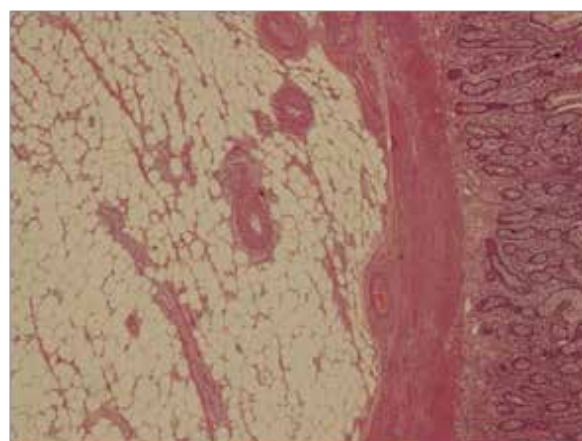


Figure 3: Examination under high power field 200 magnification: The polypoidal mass shows circumscribed submucosal lesion consist of uniform mature adipocytes separated by thin intervening fibrous septae.

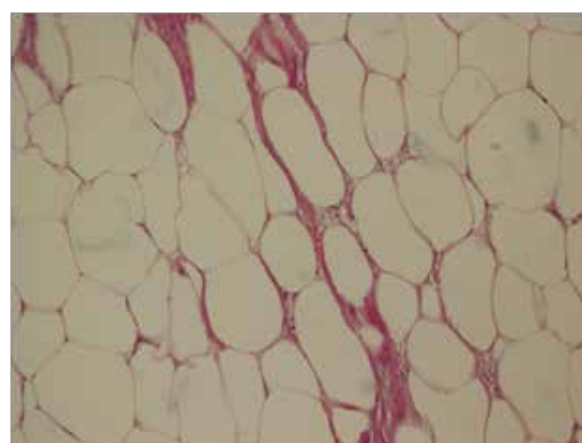


Figure 4: Examination under high power field 400 magnification: Uniform mature adipocytes.

extend into the muscularis propria and subserosal⁵. It is mainly found on the right side of the colon and caecum⁶. About 25% of patients with colonic lipoma will show symptoms. Tumour larger than 2cm in diameter can mimic malignancy symptoms such as anaemia secondary to bleeding, diarrhea, constipation, intestinal obstruction and rarely intussusception.

Various imaging techniques can infer the diagnosis of colonic lipoma. CT is among the best as it can offer fat evaluation of the tumours with Hounsfield Unit ranges from -40 till -120⁷. However, atypical CT presentation may take place especially when there is superimposed with intussusception due to varying degrees of infarction or fat necrosis. In such cases or when fibrous septa and nodularity are more conspicuous, the most accurate diagnosis is liposarcoma⁸. A more recent option to detect colonic lipoma is CT colonographic examination

(virtual colonoscopy)⁹. Its specificity is 90% and sensitivity is 86%¹⁰. It is non-invasive and can be done with no sedation. As for barium enema, the usual finding is ovoid filling defect with well-defined borders. Another frequent finding is squeeze sign, signifies a change in size and shape of the radiolucent lesion in response to peristalsis¹¹. One of the most suggested procedure is conventional colonoscopy when malignancy is suspected¹. Submucosal lipoma usually seen as smooth, spheric polypoid mass covered by mucosa⁶. The signs that can be visualized are “tending sign” (grasp the overlying mucosa) and “cushion sign” (flattening of the lipomas form)¹². Endoscopy may reveal false impression of malignancy when there is presence of ulcerative lesion of the soft polypoid mass¹³.

Main cause of malignant colon intussusception is primary colon adenocarcinoma, followed by lymphoma and metastasis⁷. 30% of colon intussusception are caused by lipomas, benign stromal tumours and adenomatous polyps. The most benign cause of colon intussusception is lipoma¹⁴. It is difficult to establish pre-operative diagnosis of colonic intussusception because clinical symptoms are not typically pathognomonic. In our case, intussusception was not found during surgical procedure might indicate that it was intermittent. Moreover, patient did not complain of bowel obstruction symptoms. Intussusception is still possible as lipoma itself can act as a leading point. However, since the lesion was seen as fungating/polypoid shape on

endoscopy and on CT imaging could not definitely rule out malignancy, right hemicolectomy was the best option.

Various treatment options are implied including endoscopic and open surgical removal. If the diameter of the lipoma is smaller than 2cm or pedunculated lipoma with thin stalk, endoscopic removal is generally recommended¹⁵. If a lipoma is sessile or broadly-based, it is advised to proceed with more intervensive technique as the adipose tissue is an inefficient conductor for electric current. Thus, perforation or hemorrhage is likely to occur. Most authors recommend surgery when the colonic lipoma is greater than 2cm in diameter. Some examples of surgical treatments are resection, colostomy with local excision, limited colon resection, segmental resection, hemicolectomy, or subtotal colectomy¹³.

Conclusion

Our case demonstrated that a colonic lipoma from contrasted CT abdomen would show fatty component with HU ranges from -40 to -120. The fatty component is an important sign to tell the surgeon that the lesion is benign. Perhaps, from the findings of the fatty component, it might help surgeon to opt for less invasive surgery such as endoscopic excision or laparoscopic excision. Colonic lipoma which measures more than 2cm in diameter with symptoms should be removed surgically. Colonic lipoma can be complicated with anemia, bowel obstruction and rarely intussusception.

References:

1. Atmatzidis S, Chatzimavroudis G, Patsas A, Papaziogas B, Kapoulas S, Kalaitzis S, et al. Pedunculated Cecal Lipoma Causing Colo-Colonic Intussusception: A Rare Case Report. *Case Reports in Surgery*.2012;2012:279213.
2. Vecchio R, Ferrara M, Mosca F, Ignoto A, Latteri F. Lipomas of the large bowel. *The European journal of surgery-Acta chirurgica*.1996;162(11):915-9.
3. Notaro JR, Masser PA. Annular colon lipoma: a case report and review of the literature. *J of Surgery*.1991;110(3):570-2.
4. Biswas S, Amin A, Castillo EA, Demestihis A. Large Cecal Lipoma With Overlying Ulceration Simulating Malignancy: A Case Report and Review of Relevant Literature. *J of Current Surgery*.2013;3(1):35-40.
5. Castro EB, Stearns MW. Lipoma of the large intestine: a review of 45 cases. *Diseases of the colon and rectum*.1972;15(6):441-4.
6. Rogy MA, Mirza D, Berlakovich G, Winkelbauer F, Rauhs R. Submucous large-bowel lipomas- presentation and management. An 18-year study. *The European journal of surgery-Acta chirurgica*.1991;157(1):51-5.
7. Chiang JM, Lin YS. Tumor spectrum of adult intussusception. *Journal of surgical oncology*.2008;98(6):444-7.
8. Pereira JM, Sirlin CB, Pinto PS, Casola G. CT and MR imaging of extrahepatic fatty masses of the abdomen and pelvis: techniques, diagnosis, differential diagnosis, and pitfalls. *Radiographics: A review publication of the Radiological Society of North America, Inc*.2005;25(1):69-85.
9. Johnson CD, Hara AK, Reed JE. Computed tomographic colonography (Virtual colonoscopy): a new method for detecting colorectal neoplasms. *Endoscopy*.1997;29(6):454-61.
10. Johnson CD, Chen M-H, Toledano AY, Heiken JP, Dachman A, Kuo MD, et al. Accuracy of CT colonography for detection of large adenomas and cancers. *N Engl J Med*.2008;359(12):1207-17.
11. Kaplan P. Submucous lipoma of the colon. Report of a case. *International surgery* 1971;56(2):113-7.
12. Zhang X, Ouyang J, Kim Y-D. Large ulcerated cecal lipoma mimicking malignancy. *World J Gastrointest Oncol*.2010;2(7):304-6.
13. Katsinelos P, Chatzimavroudis G, Zavos C, Pilpilidis I, Lazaraki G, Papaziogas B, et al. Cecal lipoma with pseudomalignant features: a case report and review of the literature. *World J Gastroenterol*.2007;13(17):2510-3.
14. Gollub MJ. Colonic Intussusception: Clinical and Radiographic Features. *American Journal of Roentgenology*.2011;196(5):W580-W5.
15. Jiang L, Jiang L-S, Li F-Y, Ye H, Li N, Cheng N-S, et al. Giant submucosal lipoma located in the descending colon: a case report and review of the literature. *World J Gastroenterol*.2007;13(42):5664-7.